

CASE STUDIES

**HUNTLEIGH**

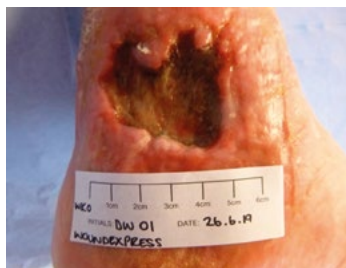A MEMBER OF THE ARJO FAMILY

# WoundExpress™

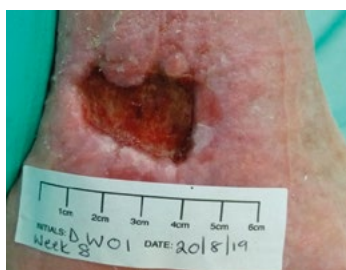Advanced Wound Therapy Device



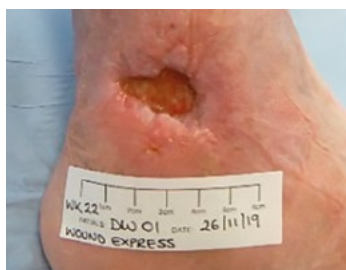
# Case Study 1



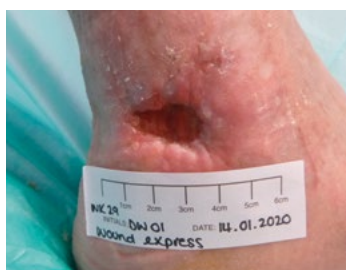Baseline size: 15.96cm<sup>2</sup>



Week 8 size: 9.25cm<sup>2</sup>



Week 22 size: 3.38cm<sup>2</sup>



Week 29 size: 2.64cm<sup>2</sup>

## History:

74 year old male patient with a 5 year history of non-healing venous leg ulcer to his left lateral malleolus.

## Treatment:

Alginate with two layer compression system (40mmHg).

Non-healing 5 years

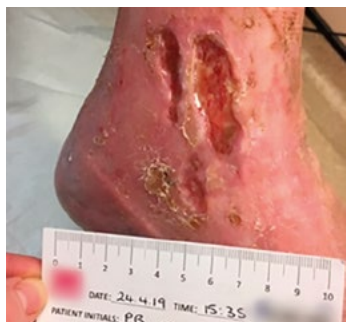Reduced by 83%

## Results following WoundExpress therapy:

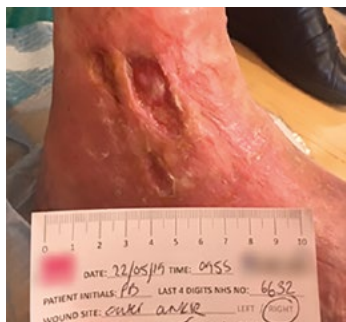- Wound decreased in size by 83%
- The oedema in his limb and the shape of the limb has improved
- Quality of his peri-wound skin has improved greatly
- Prior to inclusion in the evaluation, this patient had problems with recurrent wound infections - but the patient has been infection free for the whole duration of the evaluation (29 weeks)
- Patient feels more positive about the future of his wound and believes that it will heal for the first time in 5 years

**REDUCED  
by 83%**

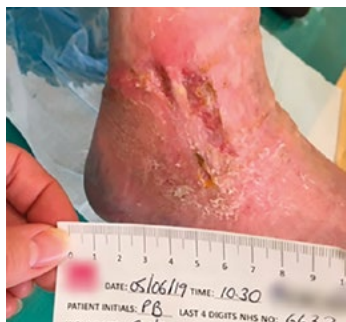# Case Study 2



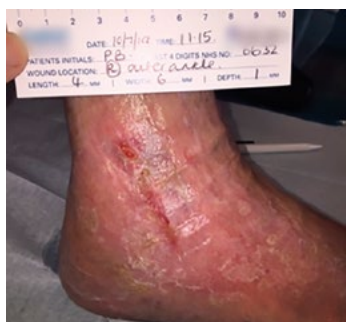Baseline



Week 4



Week 6



Week 11

## History:

71 year old female with a history of venous leg ulceration to her right lateral malleolus for two and a half years.

## Treatment:

Alginate with silver, plus two layer compression system (40mmHg).

Non-healing 30 months

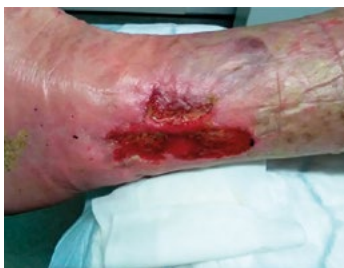Healed in 14 weeks

## Results following WoundExpress therapy:

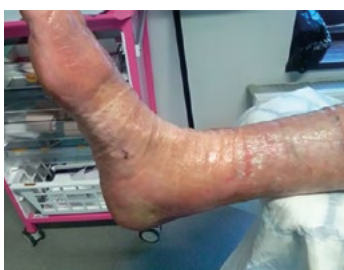- Healed and went into compression stocking at week 14

**HEALED  
within  
14 weeks**

# Case Study 3



Baseline size: 17cm<sup>2</sup>



Week 5: Healed

## History:

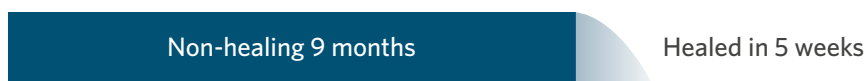82 year old male patient with 9 month history of venous leg ulcer to his medial malleolus.

## PMH:

Sarcopenia.

## Treatment:

Non-adherent dressing plus short stretch bandaging.



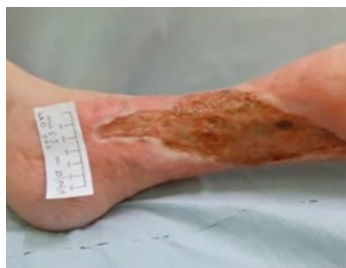## Results following WoundExpress therapy:

- Healed after 5 weeks
- Patient felt the WoundExpress helped the wound to heal
- Patient reported that his leg became 'warm and tingly' when using the device

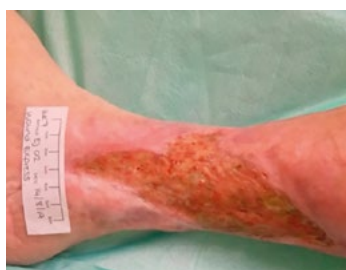**HEALED  
within  
5 weeks**



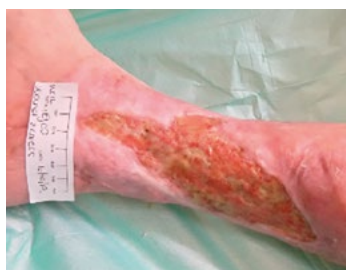# Case Study 4



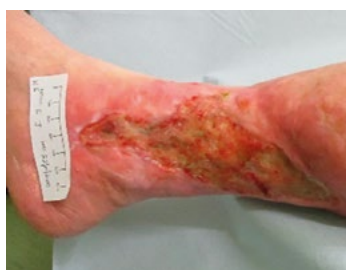Baseline size: 133.45cm<sup>2</sup>



Week 16 size: 100.5cm<sup>2</sup>



Week 18 size: 93.2cm<sup>2</sup>



Week 22 size: 92.95cm<sup>2</sup>

## History:

72 year old female with 12 year history of non-healing venous leg ulcer to right lateral malleolus/calf.

## PMH:

Type II diabetes mellitus, hypertension.

## Treatment:

Alginate plus adjustable short-stretch compression wrap system.

Non-healing 12 years

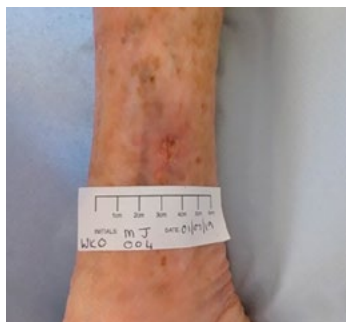Reduced by 30%

## Results following WoundExpress therapy:

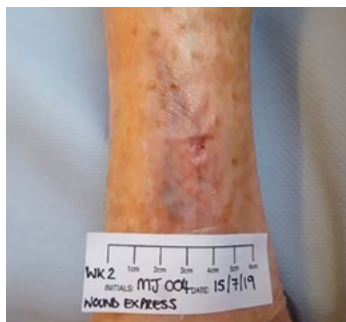- Wound size reduction of 30%
- Patient noted a significant reduction in pain. Prior to taking part in the evaluation this lady had to take oramorph prior to dressing changes as the pain was 'intolerable'. She now has no pain and does not need to take any analgesia
- Patient feedback: easy to use and fit around daily routine, comfortable

**REDUCED  
by 30%**

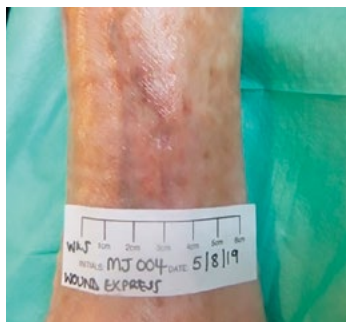# Case Study 5



Baseline



Week 2



Week 5: Healed

## History:

89 year old female with 16 month history of venous leg ulcer to right gaiter.

## PMH:

Type II diabetes mellitus, gout, atrial fibrillation, osteoarthritis, hypertension, CKD stage 3.

## Treatment:

Alginate plus modified compression.

Non-healing 16 months

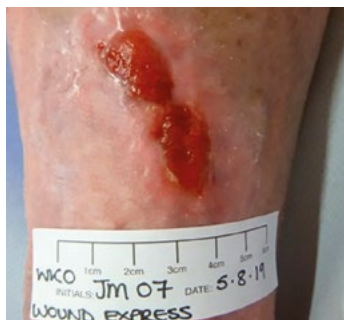Healed in 5 weeks

## Results following WoundExpress therapy:

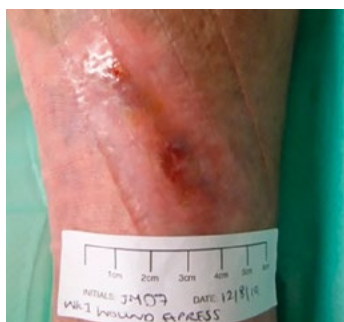- Wound healed at week 5
- Patient feedback: restless legs improved, less pain, device comfortable to use
- This lady had a small ulcer that was non-healing despite being in modified compression and having regular dressing changes. This chronic ulcer was withholding her operation for a knee replacement, which caused her a lot of pain and discomfort. After enrolling in the WoundExpress evaluation, she healed at week 5 and went on to have her knee replacement. She has since remained healed

**HEALED  
within  
5 weeks**

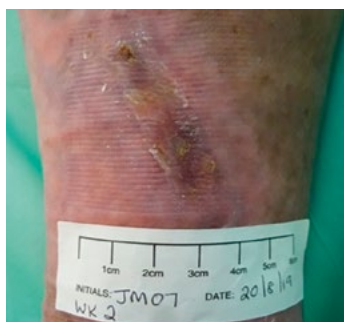# Case Study 6



Baseline size: 4.5cm<sup>2</sup>



Week 1 size: 0.09cm<sup>2</sup>



Week 2: Healed

## History:

77 year old male with 13 month history of venous leg ulcer to the left lateral gaiter. Despite treatment with gold standard compression, this wound failed to heal.

## Relevant PMH:

Venous eczema, neuropathic pain.

## Treatment:

Alginate plus two layer compression system.

Non-healing 13 months

Healed in  
2 weeks

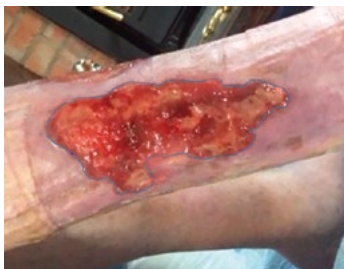## Results following WoundExpress therapy:

- Following addition of WoundExpress therapy this wound healed by week 2
- Patient feedback: using the device was 'soothing, comfortable'

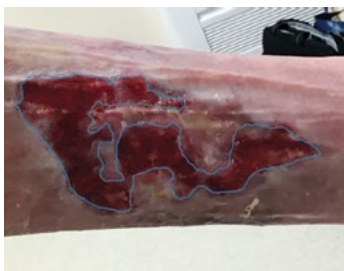
**HEALED  
within  
2 weeks**

# Case Study 7

## Lateral Leg Wound

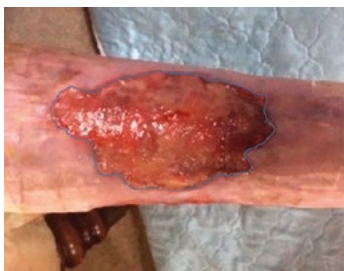

Baseline Size: 36.4 cm<sup>2</sup>

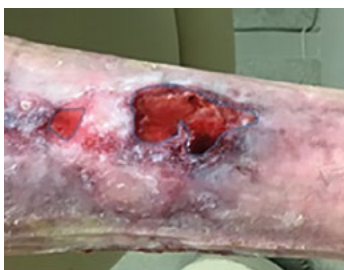

20 weeks size: 22.8 cm<sup>2</sup>

## Anterior Leg Wound



Baseline size: 47.4cm<sup>2</sup>



20 weeks size: 5cm<sup>2</sup>

### History:

83 year old male with 3 year history of extensive ulceration to right leg.

### PMH:

Multiple DVTs and PEs

Wound related pain was a major issue for this patient; he was taking 40mg MST twice daily with oramorph for breakthrough pain.

### Treatment:

Zinc paste bandage with two layer compression system (40mmHg).



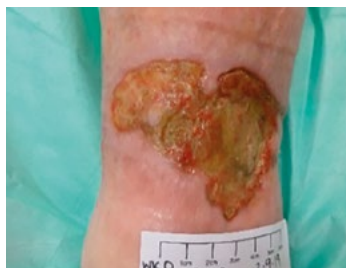### Results following WoundExpress therapy:

- Anterior wound: 89% wound surface area reduction
- Lateral wound: 37% reduction in wound surface area
- Patient reports significant reduction in wound related pain. He is no longer requiring oramorph for breakthrough pain and has reduced his dose of MST

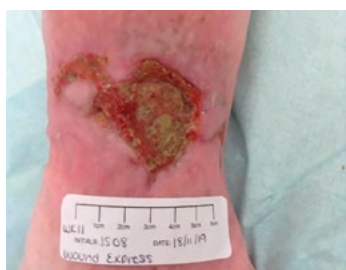
**REDUCED  
by 89%**



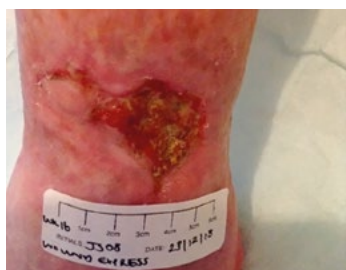# Case Study 8



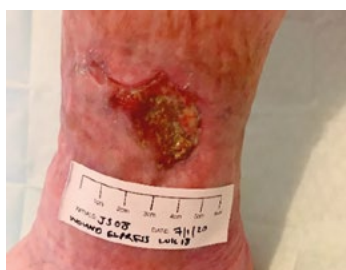Week 0 size: 63.84cm<sup>2</sup>



Week 11 size: 31.4cm<sup>2</sup>



Week 16 size: 18.2cm<sup>2</sup>



Week 18 size: 10.5cm<sup>2</sup>

## History:

74 year old female with venous leg ulcer to her left lateral gaiter (duration 3.5 years).

## Treatment:

Alginate plus adjustable short-stretch compression system.

Non-healing 3.5 years

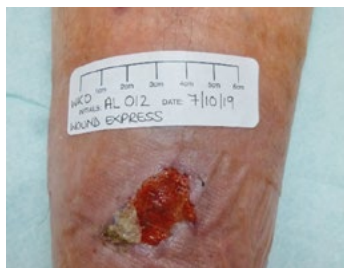Reduced by 84%

## Results following WoundExpress therapy:

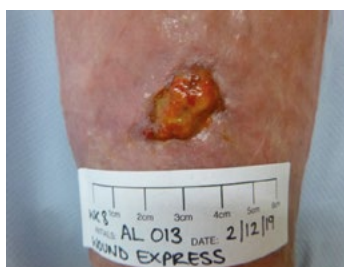- Wound decreased in size by 84%
- Visual analogue pain score reduced from 91 to 7
- Prior to inclusion in the evaluation, this patient had problems with recurrent wound infections - but the patient has been infection free for the whole duration of the evaluation (18 weeks)
- Patient finds device comfortable and easy to use (lives alone)

**REDUCED  
by 84%**

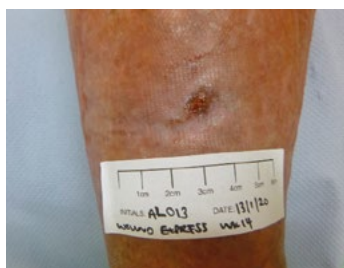# Case Study 9



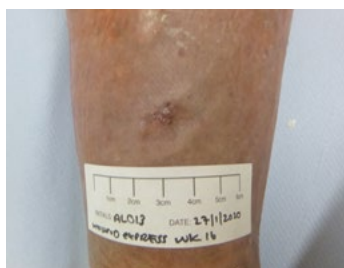Week 0 size: 7cm<sup>2</sup>



Week 8 size: 3.68cm<sup>2</sup>



Week 14 size: 0.24cm<sup>2</sup>



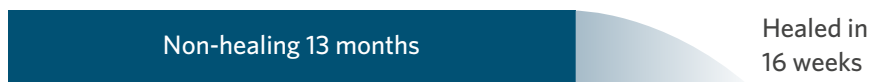Week 16: Healed

## History:

50 year old lady with a venous leg ulcer to her right lateral gaiter (duration 13 months). Patient has lymphoedema and is also under the care of the local lymphoedema service.

## Treatment:

Non-adherent dressing plus adjustable short-stretch compression wrap system.



## Results following WoundExpress therapy:

- Healed in 16 weeks
- This lady was attending her practice nurse twice weekly and couldn't bare the sight of her wound - she found it quite upsetting and wouldn't dress it herself. Once her wound had begun to heal, she began to take more ownership of her wound care and agreed to dress it herself once a week. Hence she was then able to reduce her practice nurse visits to once a week instead of twice.
- This patient found the WoundExpress therapy easy to use and fit into her routine; she found it comfortable and effective in healing her ulcer

**HEALED  
within  
16 weeks**



